

ELEVATE  
PEDIATRICS  
EVIDENCE-BASED PRACTICE

# Red Flags



1

---

---

---

---

---


---

---


---

ELEVATE  
PEDIATRICS  
EVIDENCE-BASED PRACTICE


## Areas you must address




Core Body Temperature




State of Arousal




Breathing



Peripheral Circulation



Fluid Intake



2

---

---

---

---

---

---

---

---



ELEVATE  
PEDIATRICS  
EVIDENCE-BASED PRACTICE

## Fever

> 38 Degrees

Refer...

- Infant < 28 days of age
- Fever + other red flags
- > 3 days duration in a child who is on antibiotics



3

---

---

---

---

---

---

---

---

## Arousal


Refer...

- Drowsiness and low tone
- Not responding to any stimulation

## Crying

Refer...

- Weak or moaning cry
- High pitched cry



4

---

---

---

---

---

---


---

---

## Oxygen

Refer...

- Nasal flaring
- Recession of sternum or chest wall
- Cyanosis or general Pallor
- Cold lower legs from knees down
- Grunting respiratory Sounds
- Periods of Apnoea



5

---

---

---

---

---

---


---

---

## Fluid Intake

Refer...

- 4 or less wet diapers over 24 hour period
- Sunken fontanelle
- Sunken eyes
- Dry mucous membranes
- Skin turgor



6

---

---

---

---

---


---

---


---

ELEVATE  
PEDIATRICS


## Areas you must address




Core Body Temperature




State of Arousal



Breathing



Peripheral Circulation



Fluid Intake

ELEVATE  
PEDIATRICS

---

---

---

---




---

---

---

---

7

**Bulging fontanelle**

**Petechial rash (non blanching)**




**Bile stained vomit**

**Faecal blood**

**Convulsions**

**Focal neurological signs**

**Positive Hip Dysplasia signs**

ELEVATE  
PEDIATRICS

---

---

---

---

---


---

---

---

8

## Low Back Pain in a child?



**Refer on...**

- < 4 YEARS OLD
- > 4 WEEKS DURATION
- NEUROLOGICAL SIGNS
- PAIN AT REST OR AT NIGHT

ELEVATE  
PEDIATRICS

---

---

---

---

---

---

---

---

9

## Limping Child?

**Red Flags...**

- Fever
- Red / hot joint
- Weight loss / malaise
- Night pain
- Systemically unwell
- No obvious reason for limping



ELEVATE  
PRACTICE  
EVIDENCE • 2018

10

---

---

---

---

---


---

---

---

## Problems not to be missed

What are the Red Flags suggesting?



11

---

---

---

---

---

---

---

---


## Dehydration

*Produced by a combination of reduced fluid intake and increased water loss.*

Refer...

- Sunken fontanelle
- Reduced wet nappies
- Fever
- Dry membranes
- Sunken eyes
- Skin turgor

Refer to hospital immediately



ELEVATE  
PRACTICE  
EVIDENCE • 2018

12

---

---

---

---

---

---

---

---


**Pneumonia/  
Bronchiolitis**

*Lung infection or inflammation that can reduce the amount of oxygen that can get into the body*

Refer...

- Chills, coughs and fever (older child)
- Cyanosis
- Nasal flaring
- Chest or sternal recession

Refer to hospital immediately



ELEVATE  
PEDIATRICS  
EVIDENCE-BASED

---

---

---

---

---

---

---

---

13

**Encephalitis**

*Inflammation of the brain. Can often occur with meningitis*

Refer...

- Bulging of fontanelle
- Screaming spells in infants
- Older child: headaches, nausea, vomiting, neck stiffness, focal neurological signs

Refer to hospital immediately



ELEVATE  
PEDIATRICS  
EVIDENCE-BASED

---

---

---

---

---

---


---

---

14

**Meningitis**

*An inflammation of the meninges surrounding the brain and spinal cord caused by bacterial, viral or fungal infection*



ELEVATE  
PEDIATRICS  
EVIDENCE-BASED

---

---

---

---

---

---

---

---

15

**Infants:**

- Vomiting, lethargy, altered sleep pattern
- Irritability
- Fever (early on in condition)
- Bulging fontanelle (late in condition)
- Petechial rash

**4 - 24 months**

- Fever and irritability (early on in condition)
- Nuchal rigidity
- Decreased level of consciousness (late in condition)
- Petechial rash

**> 2 Years Old:**

- Headache
- Stiff neck
- Fever
- Brudzinkis sign (bending forward produces flexion of legs)
- Kernig's sign (inability to extend knee when leg is flexed at hip)
- Petechial rash




---

---

---

---

---

---

---

---

16

## Appendicitis

*An inflammation of the appendix*

Refer...

- Pain begins at belly button then moves over to lower right quadrant
- Positive rebound test (sometimes)
- Loss of appetite
- Loose bowels
- Nausea and sometimes vomiting
- Fever

Refer to hospital immediately




---

---

---

---

---

---

---

---

17

## LIMPING CHILD?

It's a symptom, not a diagnosis.  
What are the differentials?

---

---

---

---

---

---

---

---

18

## LIMPING CHILD?

Osteomyelitis  
Septic Arthritis  
Developmental Hip Dysplasia  
Transient Synovitis  
Slipped Capital Femoral Epiphysis  
Cancer / Malignancy



19

---

---

---

---

---

---

---

## Osteomyelitis

*Infection of the BONE*

Refer...

- Fever
- Pain
- Limited use of limb
- Tenderness and swelling

Refer to hospital immediately



20

---

---

---

---

---

---

---

## Septic Arthritis

*Infection of the JOINT*

Refer...

- Child likely became unwell rapidly
- Painful joint
- Tenderness in surrounding areas of joint
- Swollen and hot Joint
- Fever
- Infants: Irritability and/or fever

Refer to hospital immediately



21

---

---

---

---

---

---

---

## DDH

The abnormal development of the hip joint where the head of the femur is not stable within the acetabulum

Refer...

- Asymmetrical skin folds
- Leg length discrepancies
- Buttocks flattening
- Walking with affected leg in external rotation
- Positive Ortho Tests

Refer for x-rays if over 6 months or ultrasound if under 6 months old



---

---

---

---

---

---

---

---

22

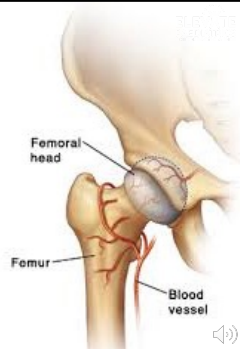
## Legg-Calve-Perthes

An interruption to the blood supply to the head of the femur which can lead to deformity

Refer...

- Hip and/or knee pain
- Insidious onset
- Worsens with exercise
- Boys from 4-8 years old (average)

Refer for hip radiographs



---

---

---

---

---

---

---

---

23

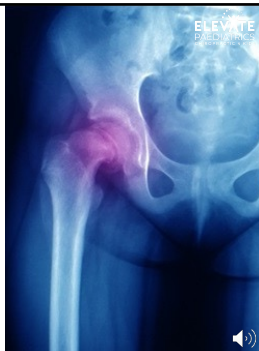## SCFE

Slipped Capital Femoral Epiphysis occurs when the top of the femoral head slips backwards before the growth plate fuses

Refer...

- Late childhood / Early adolescence
- Usually male
- Pain in anterior thigh, knee or groin
- Overweight
- Limping

Refer for hip radiographs



---

---

---

---

---

---

---

---

24

ELEVATE  
PEDIATRIC  
PRACTICE

## Transient Synovitis

*Inflammation of the lining of the hip joint.  
Also known as irritable hip  
Diagnosis of EXCLUSION.*

**Rule out other differentials first.**

2-8 years old following a viral illness.  
Limping but otherwise appears well

Speaker icon

25

---

---

---

---

---

---

---

---


ELEVATE  
PEDIATRIC  
PRACTICE

## Cancer

*Approximately 1 in 600 children will develop a malignancy before the age of 15.*

Refer...

- < 4 Years with low back pain
- Persistent pain in a child of any age
- Fever, pallor, bruising or petechiae, bone pain
- Any unusual mass or swelling
- Recurring morning headache
- Bone pain or night pain
- Persistent severe unexplained pain
- Unexplained weight loss
- Fever that is not responding to antibiotics



Speaker icon

26

---

---

---

---

---

---

---

---

## Non-Accidental Injury

Speaker icon

27

---

---

---

---

---

---

---

---

Shaken Impact Syndrome

- Uncertain history
- New onset of seizures
- Retinal Hemorrhages
- Altered consciousness
- Presence of new or healing extremity or rib fractures



**ELEVATE**  
PEDIATRIC TRAUMA  
FOR RESIDENTS & VISITORS



Other Red Flags:

- Bruises on area of the body not usually subject to trauma
- Fractures to skull, face or spine
- Pattern shaped burns
- Suspicious or concerning behaviour - ask more questions!

---

---

---

---

---

---

---

---

28

**Now what...?**




---

---

---

---

---

---

---

---

29